

Research Article

## Effect of Pyridine on the Histological Structure of Adult Rabbits Lungs *Orectolagus Cuniculus*

Thekra Atta Ibrahim and Shahad saed salman

Department of Biology, College of Education for Pure Science, Diyala University, ,Baquba- Iraq

\*Corresponding Author

THEKRA ATTA IBRAHIM

**Abstract:** The current study aimed to know the effect of pyridine on the histological structure of the lungs in rabbits. The study included 15 rabbits, with different ages ranging between 9-6 months and with different weights from (1.100-1.653) kg. The animals were divided into three groups, and each group contained 5 rabbits. The animals were placed independently and were as follows: the first group was the control group, and the second and third group were the experimental groups and included 5 rabbits for each group. Animals were injected with pyridine under the gel at a concentration of (100,200) µl of pyridine/kg of body weight for 30 days at one concentration for each group. After completing the experiment, the animals were sacrificed, dissected and extracted from the lungs, and their tissue sections were prepared. The results of the current study showed clear changes in the weights of rabbits treated with pyridine, as the weights of all experimental group animals decreased, and this decrease was affected by the increase in concentration, reaching a bear (0.850-1.400) kg. The current study of all animals treated with pyridine showed clear histological changes to the histological structure of the lungs, which included the occurrence of necrosis and separation of cells of the epithelial layer lining the bronchioles, the emergence of pulmonary oedema, macrophages, active transport vesicles, congestion and haemorrhage, and there was also an enlargement of the muscle layer, infiltration and cellular accumulation in the affected places. Severe congestion of the alveoli and rupture of the alveolar septa, as well as a change in the thickness of the alveolar septa, which led to a change in the diameters of the alveoli and an expansion in the tissue points according to the increase in concentration. The alveolar diameters in the experimental groups reached (22.8- 27.6) micrometres, respectively, compared to the control group, where its diameter was (13.6) micrometre.

**Keywords:** Adult Rabbits Lungs *Orectolagus Cuniculus*, micrometres.

### INTRODUCTION

Pyridine is a colourless to yellow liquid that has a highly flammable and foul smell. It can be made from burning coal or from coal. Chemicals and can also be formed from the breakdown of many natural substances in the environment, and there are many food flavours that contain the pyrite ring. It also evaporates very easily. If it is released into the air, it may take several months to years for it to be tolerated to other compounds. It is very easily soluble in water. If it is released into water or soil, it may degrade within days to weeks. Pyridine is used as a solvent and for many industries of different products such as medicines, vitamins, food flavours, insecticides, paints, dyes, rubber products, adhesives, and German insulation for fabrics. It is found in places around factories and water (ATSDR, 1992). It is also naturally found in wood oil in the leaves and roots of *Atrana belladonna* and in Other

plants such as coffee (furia and Bellance,1975) and tea (HO *et al.*, 2015), include cigarette smoke (Wright, 2015). In many foods such as fried chicken (Jayasena *et al.*, 2013) and French and Turkish coffee (Amanpour and Sell , 2016), agrochemicals, mainly paraquat, a non-selective herbicide, make up most of the consumption of pyridine (IHS Markit, 2014) and its molecular formula is C<sub>5</sub>H<sub>5</sub>N (Altaf , *et al.*, 2015). It is one of the most important organs that are present in the body to help breathing, and it consists of two parts: the right lung, which consists of three lobes, and the left lung consists of two lobes only, and all lobes help gas exchange as well as breathing, surrounded by a thin membrane of connective tissue called the visceral pleura and its extension inward divides the lungs into lobes and the xanthan container from the inside on the interstitial connective tissue where it is composed of connective tissue cells and mast cells where these www cells are similar in structure but differ in functions

Quick Response Code



Journal homepage:

<https://isrpgroup.org/srjmd/>

Article History

Received: 10.06.2022

Accepted: 20.06.2022

Published: 30.06.2022

Copyright © 2022 IARCON, All rights reserved. No part of this content may be reproduced or transmitted in any form or by any means as per the standard guidelines of fair use. Creative Commons License Open Access by IARCON is licensed under Creative Commons License a Creative Commons Attribution 4.0 International License.

(Caughey, 1994), the functional unit The lung are alveoli and are surrounded by septa of epithelial cells based on a companion living tissue (Grapo *et al.*, , 1978), and they are two double structures located in the weathering In the thoracic (Roberts, 2000), and that each of them consists of bronchioles within the lung and bronchioles that have a yo-yo shape embedded in connective tissue (Abdel- salam *et al.*, 2015). The lungs are also one of the most vital organs in the body and also one of the most susceptible to diseases due to their direct contact with microorganisms, toxins and colorants in the external environment. The invaders are between the teeth and blood and are more susceptible to infectious agents such as viruses in the air through respiration (Camus and Rosenow, 2004).

## MATERIALS AND METHODS

### Dosage preparation:

The dose of pyridine was prepared based on the LD50, which is valuable in rabbits (except  $\mu\text{l}$  from pyridine/ kg of body weight). Two doses of pyridine were selected to test its toxicity, namely (100 and 200) microliters, and the weights of rabbits used in the experiment ranged between (1.100 -1.653) kg. The rabbits were injected with the required amount of pyridine according to the required doses, once a day for 30 days. For each concentration, it was possible to calculate the amount of pyridine injected into rabbits used in this study based on the automated equation:

$$x/D=W_{\text{rabbit}}/1000$$

### Whereas :

x: Represents the substance to be injected into rabbits in the experiment, measured in microliters

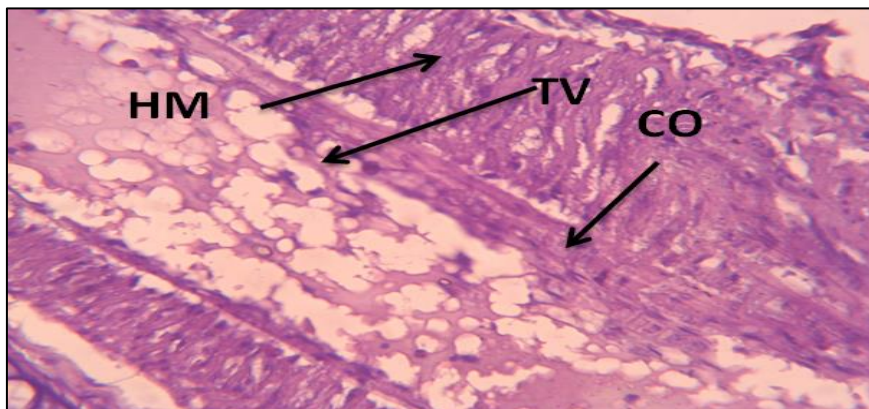
D : represents the specific dose of pyridine ( $\text{C}_5\text{H}_5\text{N}$ ) which is (100,200) units  $\mu\text{l}/\text{kg}$

Wrabbit: Weight of the rabbit used in the experiment in kg

In the current study 15 rabbits were used, and they were obtained from the animal house in the Department of Life Sciences, College of Education for Pure Sciences, University of Diyala. With different ages ranging between 6-9 months and different weights 1,100-1,653 kg. they were divided into three groups and were as follows: The first group represented the control grope , and the second and third groups represent the experimental groups, with a concentration of (100 - 200)  $\mu\text{l}/\text{kg}$  and with 5 grams for each group. the second group with a concentration of 100 for 30 days. The third group with a concentration of 200 lasted only for 19 days. After completing the experiment, the animals were dissected and the lungs were excised. Then the samples were housed in formalin solution for 24 hours, then washed with tap water and transferred to 70% alcohol for preservation. The tissue sections were prepared according to the method used in (Suvarna *et al.*, ,2013). The unstained tissue sections were prepared using Haemotoxylin and Eosin (H&E) Stain. After completing all the steps, the samples were examined and photographed using a light microscope equipped with a digital camera.

### The Results

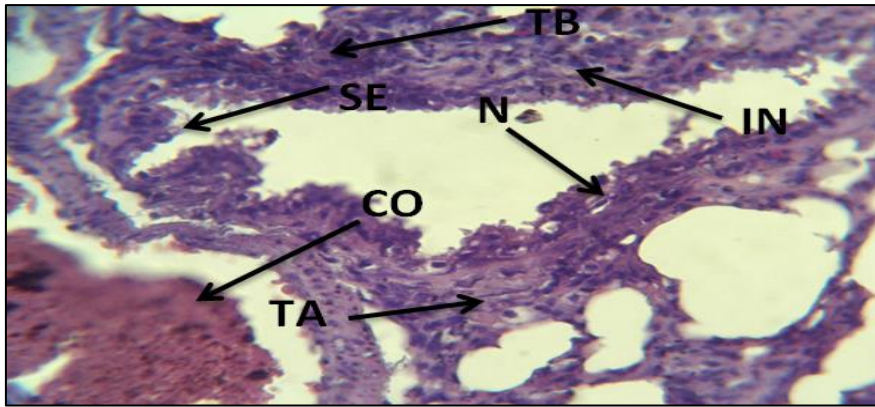
The results of the histological study of rabbit lung treated with a concentration of (100  $\mu\text{l}$  kg) of body weight and for a period of (30 dosing days) showed congestion and bleeding in the blood vessels as well as delivered in the muscle layer as in Figure (1)



**Figure (1)** A cross section of the reindeer of the experimental group treated with a concentration of 100  $\mu\text{l}$  kg of pyridine for 30 days shows CO congestion and hemorrhage in the blood vessels. HM hypertrophy of the muscular layer TV vesicles active transport. (H&E 40X)

The results also indicated the occurrence of necrosis of the epithelial lining of the bronchioles and the separation of some cells from the epithelial layer and

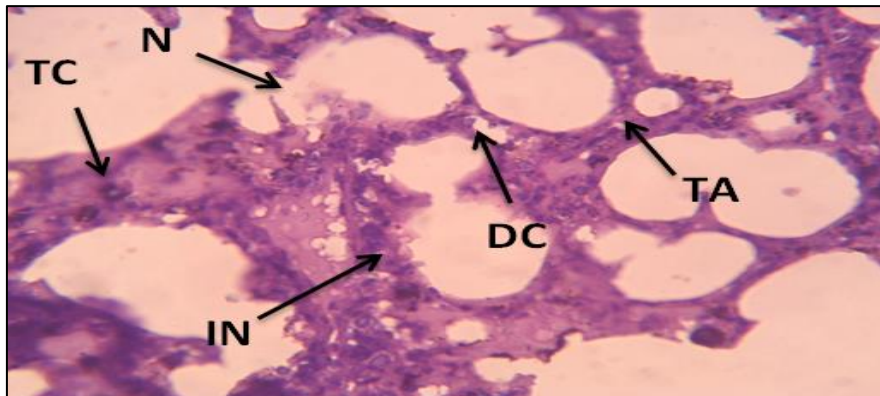
their collection in the lumen of the bronchioles.in figure (2)



**Figure (2)** A cross section of rabbit lung of the experimental group treated with a concentration of 100 µl/kg of pyridine for 30 days. N shows epithelial necrosis of the bronchioles, SE, some cells separated from the epithelial layer and collected in the lumen of the bronchioles, IN cellular infiltration, TA thickness of the alveolar wall, TB thickness of the wall of bronchioles. (H&E 40X).

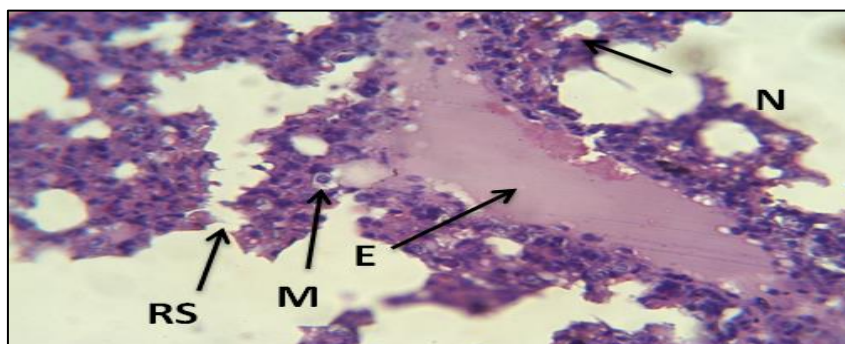
It was also shown that there was an increase in the thickness of the wall of some alveoli and alveolar ducts, which led to a change in the average of the diameters of the alveoli singles (22.6) µm compared to the control

group. which had an average diameter of (13.6) micrometers, and there was a fracture in the alveolar wall, as well as an infiltration of inflammatory cells as in Figure (3)



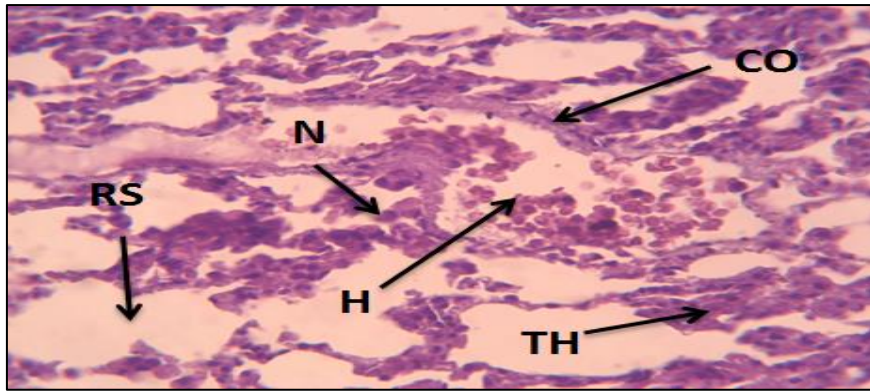
**Figure (3)** A cross section of rabbit lung of the experimental group treated with a concentration of 100 µl/kg of pyridine for 30 days. TA shows the thickness of the wall of some alveoli, TC the thickness of the wall of the alveolar duct, DC the separation of some alveolar cells and alveolar sacs, IN infiltration of inflammatory cells between the alveolar and alveolar sacs, N necrosis of the alveoli. (H&E 40)

It was also observed that there was edema between the epithelial tissue and the submucosa layer and the appearance of phagocytic cells as in Figure (4).

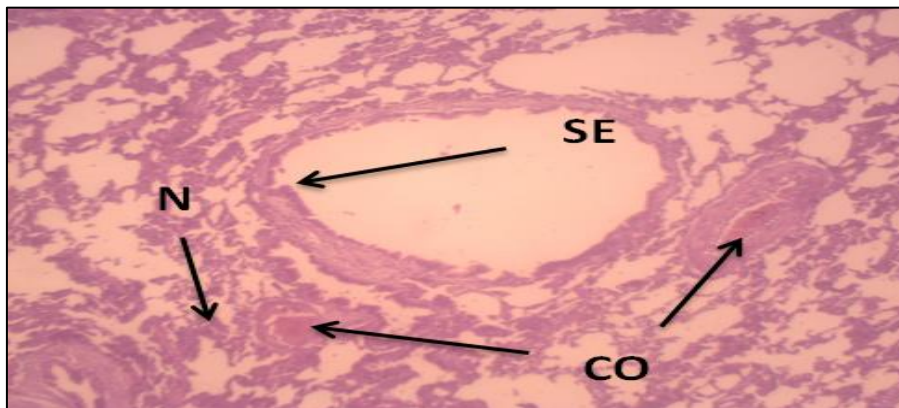


**Figure (4)** A cross section of the rabbits' lung of the experimental group treated with a concentration of 100 µl/kg of pyridine for 30 days. E shows edema between epithelial tissue and sub mucosal layer, RS interstitial barriers permeate, N necrosis, M phagocytic cells. (H&E 40X) and the use of a concentration of 200 µl/kg had a significant effect on the lung tissue and lasted for 19 days Dosing which led to the emergence of more severe and negative effects and changes from the previous focus, where it was represented by congestion and hemorrhage and the separation of some epithelial cells from their basement membrane based on it For the bronchioles, a large number of alveoli and alveolar sacs thicken, and the inter-alveolar septa separates, as well as the occurrence of necrosis in Figure (5)





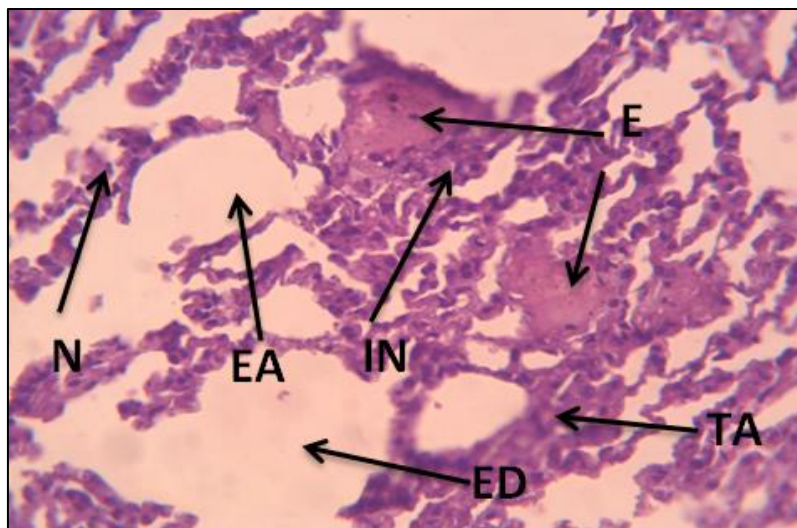
**Figure (5)** A cross section of the calf lung of the experimental group treated with a concentration of 200  $\mu$ l kg of pyridine for 19 days. TH shows thickening of the alveolar sacs and sacs, CO vascular congestion, RS, rupture of the interalveolar septum's. H hemorrhage, N necrosis. (H&E 40X)



**Figure (6)** A cross-section of rabbit lung of the experimental group treated with a concentration of 200  $\mu$ l kg of pyridine for 19 days. SE shows the separation of some epithelial cells from their basement membrane based on bronchioles, CO congestion and N necrosis (H&E 40x).

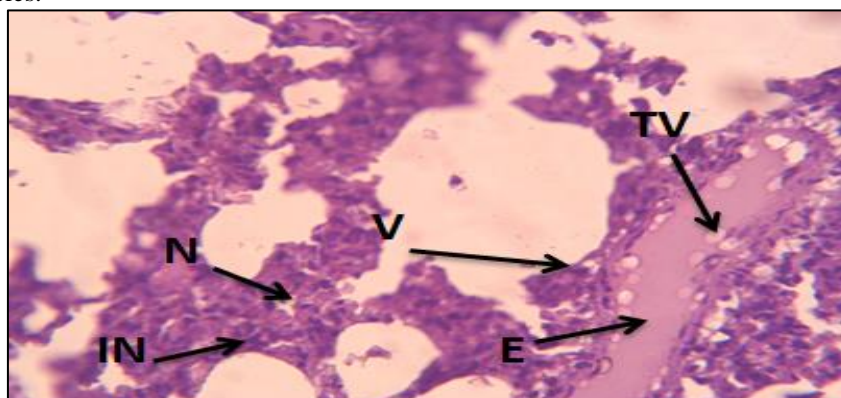
The study also showed a clear expansion of the alveolar ducts, the separation of some alveolar cells and alveolar sacs, and the occurrence of severe congestion

within the alveoli. And thickness in the wall of the cyst, and also where the infiltration of inflammatory cells is more than the previous concentration, as in Figure (7)



**Figure (7)** A cross section of the calf lung of the experimental group treated with a concentration of 200  $\mu$ l kg of pyridine for 19 days. EA shows alveolar enlargement, E edema, N necrosis TA alveolar wall thickness, ED alveolar duct dilatation, IN inflammatory cell infiltration. (H&E 40X)

As shown in Figure (8), the appearance of edema and kneading is very clear, in addition to the appearance of the active transport vesicles.



**Figure (8)** A cross section in the reindeer of rabbits of the experimental group treated with a concentration of 200  $\mu$ l kg of pyridine for 19 days, showing E edema, TV active transport vesicles, N necrosis, IN infiltration of inflammatory cells, Vaculation (H&E 40X).

## DISCUSSION

In the results of the current study, it was found that pathological changes occurred due to the decrease in the antioxidants in the animal body resulting from the chemical, represented by congestion in the blood vessels with the appearance of the blood period inside them. The cause of congestion in the blood vessels may be due to the increase in blood in the venous system, which led to an increase in blood pressure in the veins and capillaries and may put pressure on the neighboring structures, usually accompanied by a decrease in blood supply, and thus cells are exposed to malnutrition, lack of oxygen and the accumulation of excretory substances (Haschek and Rousseaux, 1991; & Rady, 2009).

The current study showed the emergence of the mark and the reason is due to the chemical pyridine and the increase of interactions leads to an increase in the vascular noise of the low-protein pyridine fluids, thus collecting in the intercellular spaces and producing it and its lameness (Kumar *et al.*, 2003). This study was conducted with (Hajhashemi *et al.*, 2014) and agreed with (ATSDR, 2012) for the effect of cadmium on rats. And the presence of erosion of inflammatory cells around the blood vessels in the tissue sections of the lungs of rabbits treated with pyridine, and the reason for this is to increase the effectiveness of the endothelial lining of blood vessels in transferring inflammatory cells migrating from parts of the body outside the peritoneum to the inside. Therefore, the vacuolated blood vessel appeared (containing vesicles Effective transfer within the vessels) and the explanation of the presence of inflammatory cells to their important effect in defending the body and trying to carry out cellular repair and this result agreed with the findings of many researchers, including (Ahmed *et al.*, 2011) (Curran and Crocker, 2005). Chemical compounds have an important role in denaturation of proteins, and they may have surface receptors on the surfaces of cells that form the walls of the alveoli and alveolar sacs, which effected the proteins of the cells, and this leads to their necrosis and degeneration. The bad parenchymal cells release

the enzymes of analysis on the large complex molecules, turning them into smaller molecules, and then the role of the phagocytes in devouring these molecules, and this may be one of the reasons for the rupture of the walls of the teeth and alveolar sacs (Curran and Harnden, 1972). While the researcher (Ritter, 1977) showed that necrosis in lung cells could be either due to a progressive degenerative action of enzymes within the damaged cells, or due to a metabolic disorder, or the slowing down of the necessary structure of DNA and thus impeding the synthesis of important and essential proteins for the growth and exudation of cells While the researchers (Giray *et al.*, 2001) indicated that such histological changes can be attributed to a decrease in the antioxidants in the animal body due to the chemical substance of the masters. Result with (Kulturoglu *et al.*, 2022). It was also noted that the thickness of the alveolar walls increased in some areas and the decrease in their cavity, which is believed to be the result of the expansion of the alveoli and sacs. Which led to this expansion putting pressure on the alveoli that make up the edges of the lung and thus led to increased pressure and made it characterized by the increase in the thickness of its walls. Its lumen has decreased, and this result is consistent with the researchers' study (Kumar *et al.*, 2003).

## CONCLUSIONS

Pyridine has clear effects that appeared in the tissue of the lungs in adult groin, where treatment with pyridine and different doses for a month caused severe pathological tissue damage to the lung, represented by the occurrence of congestion, haemorrhage, the appearance of rupture, the separation of part of the epithelial layer of the bronchi from the basement membrane and the occurrence of intercellular necrosis, as well as an effect on the average diameters Pulmonary alveoli.

## Recommendations

It is important to be fully aware of the effect of chemicals and care must be taken when dealing with them Using Immunohistochemistry to know changes in the histological structure of the lungs when using pyridine, parts of studies at the level . Molecular to see the effect of pyridine on genes and the occurrence of mutations.

## REFERENCES

1. Abdel-salam, L.R., Hussein, F.A., Gad, M.H., Khattal, A.A.A., Elhawari, W.A., Amer, A.H., & Sheriff, D.S. (2015), "Light and Epithelium of the One- Humped Camel (camelus Dromedarius)", *Med. Res. Chron.* 2(5),649-686.
2. Ahmed, D. H. (2011). "The effect of Rifampicin and Isiniazid on liver and lung tissues in rats", *Iraqi Journal of Pharmacology.* 11(2) pp: 34-45.
3. Altaf, A. A.; Shahzad ,A.; Gul ,Z.; Rasool, N.; Badshah ,A.; Lal ,B. and Khan ,E. (2015), A review on the medicinal importance of pyridine derivatives . *Journal of Drug Design and medicinal Chemistry*,1(1):1-11.
4. Amanpour, A. and Selli, S. (2016), Differentiation of volatile profiles and odor activity values of Turkish coffee and French press coffee. *J Food Process Preserv.* 40(5):1116–1124. doi:10.1111/jfpp.12692
5. ATSDR (1992). Toxicological profile for pyridine (TP-91/24). Atlanta (GA), USA: Agency for Toxic Substances and Disease Registry; pp. 1–108.
6. ATSDR (2012). Agency for Toxic Substances & Disease Registry. *Toxicological Profile for Cadmium*. Atlanta, GA, U.S. Department of Health and Human Services, Public Health Service
7. Camus, P. and Rosenow, E. (2004), Latrogenic lung disease . *Clin. Chest. Med.* , volume 25 . pp:xiii-xix.
8. Caughey, G.H.(1994) ,Serine proteinases of Mast Cell and Leukocyte Granules: A League of Their Own. *American Journal of Respiratory and Critical Care Medicine.*,150:138-142.
9. Crapo, J. D., Peters-Golden, M., Marsh-Salin, J., & Shelburne, J. S. (1978). Pathologic changes in the lungs of oxygen-adapted rats: a morphometric analysis. *Laboratory investigation; a journal of technical methods and pathology*, 39(6), 640-653.
10. Curran, M., & Harnden, D. (1972). "The pathological Basis Of medicine", Wiliam Heinemann Medical books Limited London, pp:64-80.
11. Curran, R. C., & Crocker, J. (2005). "Currans Atlas of Histopathology". 4th Edition. Harvey Miller Publishers Oxford University Press. pp:74-225.
12. Furia, T.E., & Bellanca, N. , editors (1975). Fenaroli's handbook of flavor ingredients. 2nd ed. Cleveland (OH), USA: CRC Press.
13. Giray, S.; Gurby, A. and Hinealm, F. (2001). "Cypermethrin induced oxidative stress in rat brain and liver is prevented by Vit-E or allopurinol", *Toxicology Letters, Volume 118*, pp: 139-146.
14. Hajhashemi, V.; Mojiri-Froshani, H.; Saghaei, L. and Fassihi, A.(2014).A study on the anti-inflammatory effects of new derivatives of 3-hydroxy pyridine-4-one. *Adv Biomed Res* ;3:134.
15. Haschek, W. M., & Rousseaux, C. G. (1991). "Hand book of toxicological pathology". Academic Press, London and New York
16. Ho, C.T.; Zheng, X., & Li, S. (2015), Tea aroma formation. *Food Science and Human Wellness*, 4(1):9–27. doi:10.1016/j.fshw.2015.04.001
17. IHS Markit (2014). Pyridines. Chemical economics handbook. Available from: <https://ihsmarkit.com/products/pyridines-chemical-economics-handbook.html>
18. Jayasena, D.D. ; Ahn, D.U.; Nam, K.C. and Jo, C. (2013), Flavour chemistry of chicken meat: a review. *Asian-Australas J Anim Sci*, 26(5):732–742. doi:10.5713/ajas.2012.12619 PMID:25049846
19. Kulturoglu, G., Ergil, J., Kulturoglu, M.O., Yalcindag, A., & Onder, E.O.(2022).The effects of hydroxyurea on proinflammatory cytokine and tissue histopathology in an experimental sepsis model. *European Review for Medical and Pharmacological Sciences.*26, 526-533
20. Kumar, U., Cotran, R. S., & Robbins, S. L. (2003). "Robbins Basic pathology", 7th Edition. Saunders Comp. pp: 4-781.
21. Rady, M.I. (2009).Effects of exposure to diazinon on the lung andsmall intestine of guinea pig , histological and somehistochemical changes. *Braz Arch Biol Technol (52)* : 317-326
22. Ritter, E. J. (1977). "Altered Biosynthesis. In: Handbook of Teratology", Volume 2, Plenum Press, New York. Sendecor.
23. Roberts, F. (2000),Respiratory Physiology, *Physiology.* 12(11):1-3
24. Wright , C. (2015), Standardized methods for the regulation of cigarette-smoke constituents. *Trends Analyt Chem*, 66:118–127. doi:10.1016/j.trac.2014.11.011
25. Suvarna , S. K. ;Layton, C. and Bancroft, J.D. (2013). "Bancrofte' s Theory and Practice of Histologixal Techniques" E-Book. Elsevier Health Sciences. Elsevier, Churchill Livingston :603.